

Violence of Undetermined Origin: A Case Report

*Murkey P.N, **Tirpude B.H, *** Pawar V.G, *** Shende S.A, ***K.Suken Singh, ***Keche A.S.

*Associate Professor, **Professor & Head, ***Postgraduate students
Department of Forensic Medicine & Toxicology,
Mahatma Gandhi Institute of Medical Sciences, Sewagram.

Abstract

On 09/02/08, 20 years old married women, primigravida, with her husband after attending regular Antenatal checkup at PHC at Hinganghat sector, was going back to her home met with an accident, then immediately taken to Government hospital near to the accident site, from their referred to Kasturba Hospital, Sewagram. She gets admitted and treatment started but did not survived during the treatment. The investigating officer made Panchnama and body was sent for postmortem examination. The husband was crying very agonily and saying that this was their first issue in their family. Though 7 people were present in the auto rickshaw, only my wife has injured seriously and others were having minor injuries, added to that says-"Kaal ala hota, pan vel aali navthi, devane mala pan ka barobar nele nahi" Case has been explained in details.

Key words

Primigravida, Investigating officer, Panchnama, Postmortem.

Introduction

Accidents are epidemics in civilized

world; and our country is not an exception of this universal trend, and has witnessed a steady increase in the accidental trauma. Trauma accounts for 8% of all deaths in India. Every year in India, about 1, 40,000 individuals die in accidents.⁽¹⁾

In urban life, 75% of abdominal trauma follows blunt injury. Greatest difficulty in their management lies in the timely diagnosis other causes are fall from height, sports accidents, martial arts, athletics like high jump, mountaineering.⁽²⁾ The large area of the anterior abdomen occupied by the intestine provides a target for perforation with consequent chemical or infective peritonitis.⁽³⁾

The liver and especially spleen may bleed extensively causing a haemoperitoneum. Closed or blunt injury to the abdomen is common from both accidents and assault. The liver, intestine, spleen and mesentery are more vulnerable.⁽³⁾

Case Report

A, 20 years married primigravida, alleged to have sustained injuries in a road traffic accident due to hit by truck, while she was travelling by auto rickshaw, then immediately taken to Government hospital near to the accident site, from their referred to Kasturba Hospital, Sewagram. She gets admitted and treatment started but unfortunately

Reprint requests: Dr. P.N. Murkey

Associate Professor, Department of Forensic Medicine & Toxicology, Mahatma Gandhi Institute of Medical Sciences, Sewagram Wardha, Maharashtra.

she did not survive . As body comes for postmortem, external and internal examination has been carried out.

External examination

External examination shows averagely built nourished female body with rigor mortis present all over the body and postmortem lividity present on the back side except at the pressure points with no signs of decomposition seen. Eyes were closed with pupils fixed and dilated, mouth closed,. Reddish coloured blood like stains present at places near the natural orifices. Multiple abrasions and contusions were present mainly on the abdomen, right lower limb, right hand, anterior aspect of the left knee joint, various dimensions varying from 8cm to 5cm ,4cm to 3cm and 3cm to 2cm direction also varies.

Internal examination

On opening the skull, contusion present over the vertex with sub scapular hematoma 7cm to 5cm in size weight about 80gms involving the both parietal and occipital region. Brain matter was edematous. No hemorrhages seen in the ventricular region.

On opening the pleural cavity, lungs were pale, on cut section no oozing of blood seen and lungs were congested. Heart was normal in size and shape with no hardening and thickening of the coronaries and on cut section shows no blood in the ventricles.

Abdomen was distended, linea niagra and stria gravid arum present on the anterior aspect and breast was pendulous with both nipples were prominent. On opening the abdomen, about 1.5 liters of thick purulent blood was present in the abdomen.

Liver shows the two lacerations on the anterior aspect on left lobe about 6cm to 2cm to 4cm to 3cm in size parenchymal deep, vertical in direction, reddish colour blood clot adherent at the site of laceration. Spleen shows laceration at its medial aspect of size of 3cm to 2cm, parenchymally deep obliquely direction, on cut section pale.

Both kidneys were normal in size and shape on cut section-Cortico-medullary ratio was normal and pale. Mesentery attached to the large intestine was contused.

On opening the distended gravid uterus, retro placental blood around 200ml present with some blood clots. placental weight was of 350gms with single female child showing no signs of life was present. Length of the baby was 46cm and cord length is 42cm. Head circumference was 32cm and chest circumference was 28cm, weight of the baby with placenta was 2900gm. Eyebrows and eyelashes of the baby were present. Blackish colour hairs present on scalp with planter creases present on both feet. Presentation of the baby was vertex with.

As the case reveals all positive findings, the autopsy surgeon has no doubt in giving the final cause of death.

The final cause of death in this case is "Hemorrhage and shock as a result of injury to the organs liver and spleen".

Discussion

Injuries of the abdominal viscera caused by blunt trauma are particularly common in civilian life. The blunt trauma differs from penetrating trauma, as the different organs are characterized by

injured. The solid organs are more likely to be damaged by compression from blunt straining than the hollow viscera⁽⁴⁾

The outstanding features of injury to solid organs are the hemorrhage and shock, while in hollow visceral injury shock follows with the development of peritonitis, as the intestinal track has certain fixed points, which are vulnerable to rupture⁽⁵⁾

In open cases of abdominal trauma the clinical manifestation of diagnosis and management will be easier but closed cases of trauma, offers a great challenge to the treating surgeons⁽⁶⁾

Sometimes it may escape detection or lead to an error in diagnosis from medico legal point and same is often true with the autopsy surgeons⁽⁷⁾

Blunt force injuries of the pregnant uterus are rare. In one case, 39 years old women, five months pregnant was run over by an automobile sustain fractures and injuries present. Violence has exerted pressure on her lower portion of pregnant uterus, rupturing the fundus and amniotic sac which is three and half inches long which fetus still attached to placental site. Death occurred as a result of profuse intra abdominal hemorrhage⁽⁸⁾

The most common fatal sequel to intraabdominal trauma is hemorrhage from any of the contained organ. The spleen and mesentery bleed most copiously and quickly, though there can be delay of many hours in serious symptoms may seen⁽⁹⁾

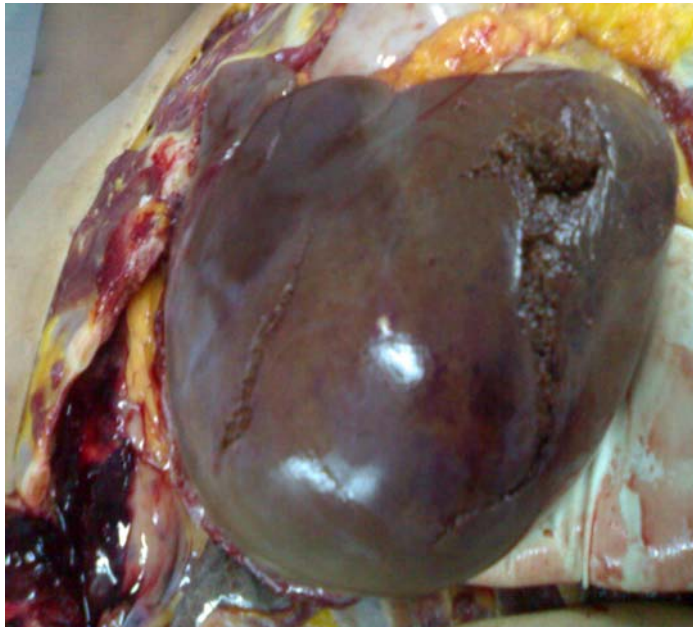
Conclusion

Our aim to present this unusual case presentation is to alert to the surgeons and gynecologist to adequately evaluate the cases of blunt trauma abdomen as injuries to organs like liver, spleen, kidney leading to hemorrhage (60%) was common cause of death. The manner of death cannot be ascertained from the visceral injuries alone. As infection is a major cause of mortality, sustained efforts to control infection can reduce the mortality. Along with this one of the suggestions to be followed for everyone is that not to drive so carelessly which can do disaster for any others family or community, which gives direct message to society to follow the road traffic rules and safe driving to minimize such incidences.

References

1. A Keith Mant. *Taylor's principles and practice of Medical Jurisprudence wounds and their interpretation, Blunt injury to the abdomen.*
2. Apurba Nandy-*Principles of Forensic Medicine.*
3. Bernard Knight, *Forensic Pathology, 2nd edition, Chest and abdominal injuries, Page no. 226.*
4. Dixon Man: *Forensic Medicine & Toxicology, special wounds and injuries.*
5. Gordan, I and H.A. Shapiro: *Forensic Medicine Guide to principles of abdominal injuries*
6. Rezek and Millard: *Autopsy Pathology, abdominal cavity*
7. Polson & Gee: *The essential of Forensic Medicine. Injuries of specific region.*
8. Sydney Smith: *Forensic Medicine injuries in various parts of the body.*
9. Francis E. Camps: *Practical Forensic Medicine Wounds sequelae and complication.*

Photograph showing the liver lacerations



Photograph showing the spleen laceration

